

Sinus augmentation with atelo-collagenated bovine bone graft Hypro-Oss™

Author_Dr Amir Gazmawe, Jerusalem

_Introduction

Xenograft materials are widely used for sinus augmentation and guided bone regeneration for increasing the availability of bone for optimal implant placement and reconstruction of bone defects. Atelo-peptidation of Hypro-Oss is an enzymatic process that is used to eliminate the antigenic telopeptide sequence of the bovine collagen chain in the bone granules and thus eliminates the immune response by using the atelo-collagenated bovine bone graft in augmentation procedures in humans. The non-immunogenic bovine collagen (atelo-collagen) goes through the process of lyophilization, which is a process of dry-freezing using sublimation that directly converts the frozen water in HYPRO-OSS™ to vapor without passing through the intermediate liquid phase. The dry-frozen materials become highly absorbent and can be stored at room temperature. Hypro-Oss™ is composed of 30% collagen type I free

of telo-peptide (atelo-collagen) with native osteoinductive elements (TGF, BMPs, IGFs) and 70% native osteoconductive bovine Hydroxyapatite components. The advantage of the lyophilized bovine atelo-collagen in Hypro-Oss™ as presence of sufficient amount of collagen type I that is essential for the turnover of bone and other bone growth peptides, such as PDGF, IGF 1, IGF 2 and TGF beta. It confers the inductivity of bone formation and gives this kind of Xenograft material an advantage upon the heated ceramic xenograft which contains zero amount of organic material and growth factors due to the heating procedures.

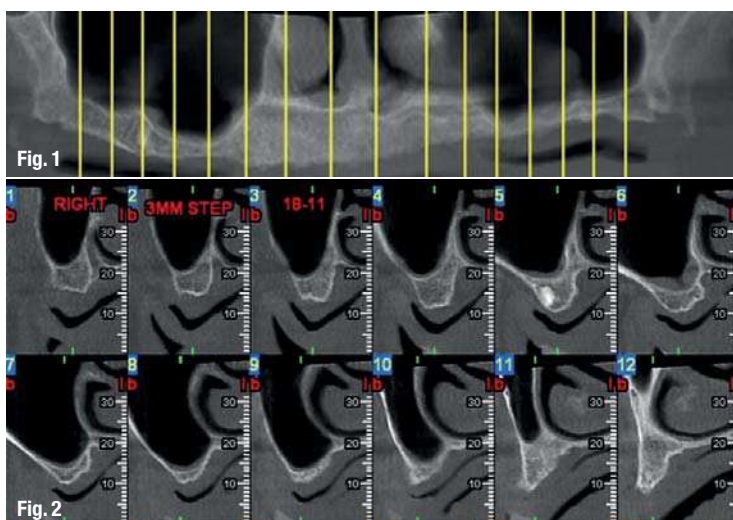
This study will evaluate the effect of bovine lyophilized atelo-collagen containing xenograft (Hypro-Oss™, Bioimplon GmbH, Germany) in sinus augmentation procedure using clinical evaluation of handling, short term healing, implantation parameters, histological screening of the augmented site 24 weeks post-augmentation and follow up until osseointegration is completed for the final loading.

_Case presentation

A 70-year-old edentulous lady with drug-stabilised hypertension has unstable maxillary complete denture. The patient was interested in fixed partial denture. Clinical evaluation of the maxilla presents atrophic ridges, unstable removable complete denture and need for massive lip support due to the atrophic jaws, in the mandible implant supported overdenture. Radiographic evaluation demonstrates the lack of bone at vertical and horizontal dimension, low sinus floor about 1–3 mm of residual bone at the sinus posterior area, the sinus anatomy is regular, no septum or membrane impairments was recorded using i-cat CT tomography scanning.

Fig. 1 Panoramic X-ray shows the atrophic maxillary ridges and the insufficient thin bone of the molar area of maxilla.

Fig. 2 i-CAT tomography of the posterior maxilla shows 2-4 mm of available bone.



Methods and materials

First stage was augmentation of the sinus floor according to the cardwell-luc approach after mid crestal incision and flap raised with releasing incision at the canine area, cutting the buccal wall of the sinus with sinus lateral elevation kit of Zimmer Dental. After membrane elevation filling the sinus volume with lyophilised atelo-collagenated bovine bone graft (Hypro-Oss™, Bioimplon GmbH), grain size 0.5–1.0 mm, filling 3 cc of material in each sinus, Saline was added five minutes before using the xenograft. The lateral window was covered with resorbable membrane that contains absorbable sterile bovine atelo-collagen (99.9% collagen type I free of telo-peptide), Hypro-Sorb M™, Bioimplon GmbH. The site was sutured with 3-0 silk sutures. Amoxicillin 500 mg TID with 250 mg of metronidazole TID was recommended for seven days after surgery.

Follow up including clinical examination was held once every two weeks and later once a month to evaluate the healing process. Radiographic examination was done at week 24 to evaluate the bone volume and a second surgery was done where implants were placed at the sinus area using flap elevation. The implant site was prepared using trephine drills



Fig. 3

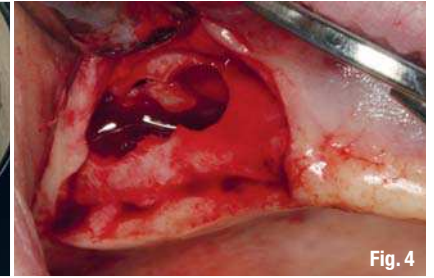


Fig. 4

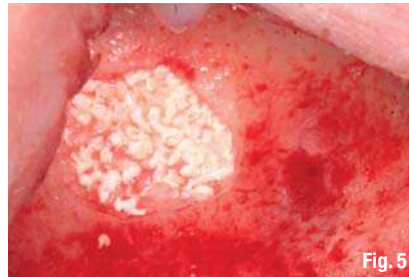

Fig. 5

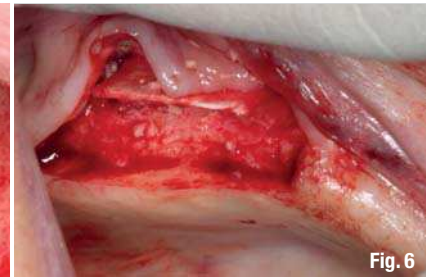

Fig. 6

2.5 mm diameter proceeded by drills according to implantation accepted protocol in addition to buccal approach biopsy using 4.5 mm trephine between implants and then filling biopsy defect with Hypro-Oss xenograft and Hypro-Sorb M membrane. The bone biopsies were sent to histological examination, placing implants at the prepared sites measuring the insertion torque-by-torque wrench tool. The histo-

Fig. 3 Hypro-Oss™-granules.

Fig. 4 Lateral window for sinus augmentation (Caldwell-luc approach).

Fig. 5 Hypro-Oss™ filling.

Fig. 6 Hypro-Sorb M™ membrane covering.

AD

*become an author
for "implants"*

[PICTURE ©SUNYVAKI]



Please contact Georg Isbaner
✉ g.isbaner@oemus-media.de

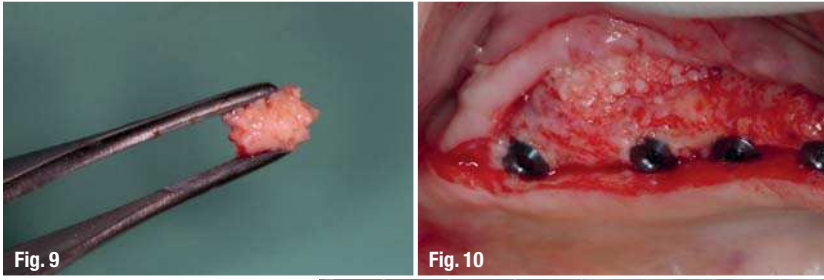
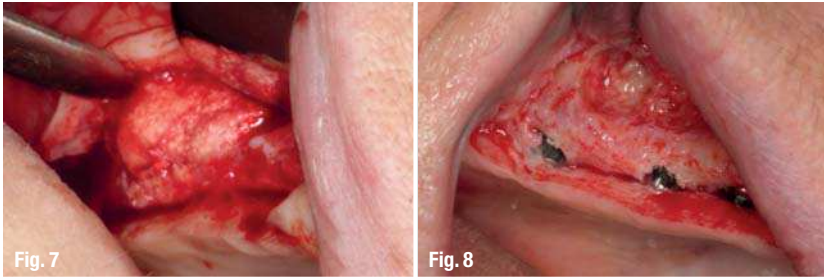


Fig. 7 24 weeks post augmentation.
Fig. 8 Implants placement and biopsy site (buccal wall).
Fig. 9 Hypro-Oss™ biopsy.

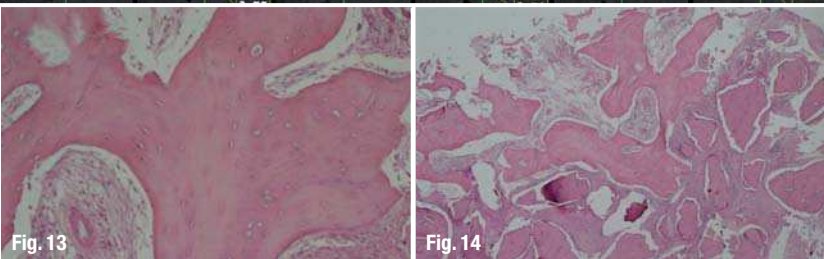
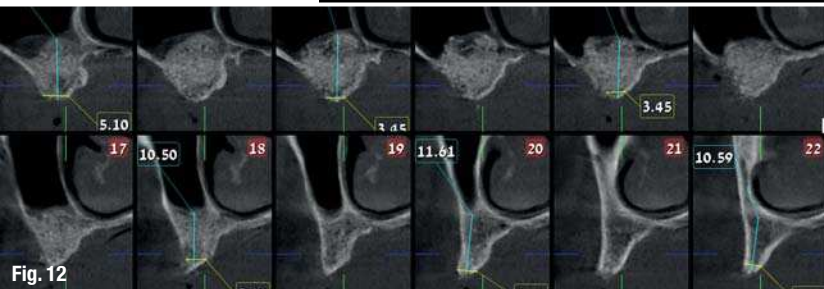
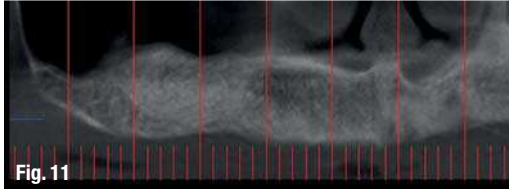


Fig. 10 Restoring the buccal biopsy site with Hypro-Oss™.
Fig. 11 Panoramic X-ray 24 weeks after augmentation shows radiographic similarity to type II natural bone.
Fig. 12 i-CAT tomography shows the new bone formation, new bone available for implant 11–13mm).
Fig. 13 Histological slides show new bone formation, multi-lacunae of osteoblast and, lamellar bone, x100 magnification.
Fig. 14 Histological slides show new bone formation, multi-lacunae of osteoblast and, lamellar bone, x20 magnification.

logical examination included freezing and H&E staining, examination using light microscopy. Three implants used in this case were root form spiral SLA coated implants. After implant incursion, implant covers were connected and the flap was sutured using 3-0 silk sutures. Amoxicillin 500 mg TID with 250 mg of metronidazole TID was recommended for seven days after surgery.

Results

The bovine lyophilized atelo-collagen containing Xenograft (HYPRO-OSS™, Bioimplon GmbH) was used for filling the Sinus. This material was hydrated with 0.9% Saline before the implantation and consequently the material was pasty with excellent han-

dling properties. Haemostatic effect appears immediately after placing into the operation site. Hydration increased the volume of the grafting material and there was no tension on sinus membrane while condensation of the grafting material. Placing the membrane (Hypro-Sorb M™) was easy, good handling, cutting, good capillary effect and stable at the site of surgery. Follow up a week after surgery presented very good healing, minimal swelling; no membrane exposure or flap opening, good wound integration or minimal discomfort for patient was reported in the following days after the two surgeries.

The bone height of the new bone was 11–1 mm at the right sinus (2–3mm of natural bone), the density of the bone was similar to Bone type II. Insertions torques of the tree implants placed at the right sinus were metered by manual torque wrench and found to be 28–30 Ncm. The histological slides demonstrated a large volume of high quality bone tissue and minimal connective tissue. New bone matrix and few old bone materials were seen in large magnification.

Conclusion

Lyophilized atelo-collagenated Xenograft (Hypro-Oss™) that is composed of 30% collagen type I free of atelo-peptide (atelo-collagen) with native osteoinductive elements (TGF, BMPs, IGFs) and 70% native osteoconductive bovine Hydroxyapatite components, can be used as an efficient inductive bone grafting material for guided bone regeneration and sinus augmentation. This work can show that this Xenograft has several advantages due to the production process that preserves the organic elements as bone growth factors that are responsible for accelerating the bone regeneration period and resulting in optimal bone quality and volume for optimising implant placement. Good bone density was approved by high implant insertion torque and high volume of calcified tissue in histological slides. The clinical and radiographical properties of the new bone are similar to natural type II bone. In addition to these advantages, a good handling during surgery, good healing and minimal post-surgical complications are also concluded upon this case.

_contact	implants
<p>Dr Amir Gazmawe DMD specialist in Prosthodontics Hadassah University—Dental Faculty Jerusalem</p>	